

Outcomes of Osteochondral Allograft Transplantation With and Without Concomitant Meniscus Allograft Transplantation

A Comparative Matched Group Analysis

Rachel M. Frank,^{*†} MD, Simon Lee,[‡] MD, MPH, Eric J. Cotter,[‡] BS, Charles P. Hannon,[‡] MD, Timothy Leroux,[‡] MD, and Brian J. Cole,[‡] MD, MBA

Investigation performed at Rush University Medical Center, Chicago, Illinois, USA

Background: Osteochondral allograft transplantation (OCA) is often performed with concomitant meniscus allograft transplantation (MAT) as a strategy for knee joint preservation, although to date, the effect of concomitant MAT on outcomes and failure rates after OCA has not been assessed.

Purpose: To determine clinical outcomes for patients undergoing OCA with MAT as compared with a matched cohort of patients undergoing isolated OCA.

Study Design: Control study; Level of evidence, 3.

Methods: Patients who underwent OCA of the medial or lateral femoral condyle without concomitant MAT by a single surgeon were compared with a matched group of patients who underwent OCA with concomitant MAT (ipsilateral compartment). The patients were matched per age, sex, body mass index, and number of previous ipsilateral knee operations ± 1 . Patient-reported outcomes, complications, reoperations, and survival rates were compared between groups.

Results: One hundred patients undergoing OCA (50 isolated, 50 with MAT) with a mean \pm SD follow-up of 4.9 ± 2.7 years (minimum, 2 years) were included (age, 31.7 ± 9.8 years; 52% male). Significantly more patients underwent OCA to the medial femoral condyle ($n = 59$) than the lateral femoral condyle ($n = 41$, $P < .0001$). Patients underwent 2.7 ± 1.7 operations on the ipsilateral knee before OCA. There were no significant differences between the groups regarding reoperation rate ($n = 18$ for OCA with MAT, $n = 17$ for OCA without MAT, $P = .834$), time to reoperation (2.2 ± 2.4 years for OCA with MAT, 3.4 ± 2.7 years for OCA without MAT, $P = .149$), or failure rates ($n = 7$ [14%] for OCA with MAT, $n = 7$ [14%] for OCA without MAT, $P > .999$). There were no significant differences in patient-reported clinical outcome scores between the groups at final follow-up. There was no significant difference in failure rates between patients undergoing medial femoral condyle OCA ($n = 12$, 15.3%) and lateral femoral condyle OCA ($n = 5$, 12.2%, $P = .665$).

Conclusion: These results imply that with appropriate surgical indications to address meniscus deficiency in patients otherwise indicated for OCA and despite the added surgical time and complexity of concomitant MAT, outcomes are favorable, with an 86% OCA graft survivorship at 5 years. This information can be used to counsel patients undergoing OCA with concomitant MAT as part of a knee joint preservation strategy.

Keywords: osteochondral allograft transplantation, meniscus allograft transplantation; knee joint preservation; clinical outcomes; concomitant versus staged

Joint preservation surgery via reparative, reconstructive, and biological techniques has become increasingly utilized over the past 2 decades.^{5,9,16,26,39} Joint preservation procedures for articular cartilage lesions include microfracture,

autologous chondrocyte implantation, surface allograft transplantation, osteochondral autograft transplantation, surface allograft procedures, and osteochondral allograft transplantation (OCA).^{14,30,34,36} Similarly, for appropriately indicated patients with symptomatic meniscus deficiency, meniscus allograft transplantation (MAT) is often recommended.^{10,35,41,42} Patients indicated for joint preservation procedures such as OCA and/or MAT are particularly challenging, as they often present after having

undergone at least 1 prior surgical procedure, they have high preinjury activity levels, and they often have high postoperative expectations. The main goals of treatment for these challenging patients are to improve function and reduce pain. In many cases, procedures such as OCA and MAT are considered “salvage” surgical procedures, as they are performed as a final effort to reduce pain and improve function for simple activities of daily living (ADL) for patients with debilitating knee pain and dysfunction. In other cases, these procedures are performed in an effort to return patients to recreational/sport activities in which they are otherwise unable to participate, owing to large symptomatic chondral or osteochondral lesions and/or symptomatic meniscus deficiency.

Several studies have demonstrated that for the majority of patients, OCA and MAT both result in excellent clinical outcomes with low complication and failure rates. Notably, many of the patients undergoing either of these procedures have combined knee disorders, including chondral lesions and meniscus deficiency, and in some cases malalignment and/or ligament instability.¹² Determining the appropriate surgical procedures for these patients is difficult, particularly in the setting of combined cartilage and meniscus deficiency. Several biomechanical, translational, and clinical studies have demonstrated the protective role of the meniscus in preventing chondral damage and degeneration.⁸ As a result, unaddressed meniscus deficiency has been considered a relative contraindication to cartilage restoration procedures such as OCA, given concerns that these patients may have less optimal outcomes. Surgical approaches to knee joint preservation that combine OCA with MAT (with realignment osteotomies and/or ligament reconstructions, when indicated) have thus been advocated for patients with multiple coexisting knee pathologic conditions, with several studies reporting favorable outcomes.^{1-4,6,7,17-24,32,38}

While OCA is often performed with concomitant MAT as a strategy for knee joint preservation, to date, the effects of concomitant MAT on outcomes after OCA have rarely been discussed, particularly in comparison to outcomes after isolated OCA. To date, only a single study is available that analyzed the postoperative outcomes of patients undergoing combined OCA with MAT.¹⁵ The purpose of this study was to determine clinical outcomes for patients undergoing OCA with MAT as compared with a matched cohort of patients undergoing isolated OCA. We hypothesized that as a result of the increased operative complexity and more involved underlying pathologic conditions of patients

TABLE 1
Factors Utilized to Match Patients Undergoing OCA
With and Without MAT^a

Age, ±3 y
Sex
Body mass index, ±5 kg/m ²
No. of previous ipsilateral knee operations, ±1

^aEach group, n = 50. MAT, meniscus allograft transplantation; OCA, osteochondral allograft transplantation.

indicated for concomitant OCA and MAT, patients undergoing the combined procedure would have inferior clinical outcomes and higher failure rates when compared with patients undergoing OCA without MAT.

METHODS

After approval from our university’s institutional review board, an analysis was conducted of prospectively collected data from patients who underwent OCA of the medial femoral condyle (MFC) or lateral femoral condyle (LFC) by a single surgeon (B.J.C.) between 2000 and 2014 with a minimum follow-up of 2 years. Patients who underwent OCA without concomitant MAT (n = 50) were matched in a 1-to-1 format (nonconsecutive) to patients who underwent OCA with concomitant MAT (n = 50). All MAT procedures were performed in the same compartment as the OCA (medial MAT for patients with MFC OCA, lateral MAT for patients with LFC OCA). The patients were matched per several factors, as listed in Table 1. Indications for OCA included symptomatic, isolated, full-thickness chondral lesions >1 cm (diameter) recalcitrant to nonoperative management, as well as failed prior articular cartilage restoration procedures. Indications for MAT included symptomatic meniscus deficiency, including prior failed meniscus surgery. When indicated, patients underwent concomitant realignment osteotomy. Indications for concomitant high tibial osteotomy or distal femoral osteotomy included the mechanical axis of the lower extremity preferentially loading or overloading the involved compartment. In these cases, the mechanical axis was corrected to neutral (center of tibial plateau) in an effort to offload the involved compartment. All procedures were performed in a single setting, as opposed to staged procedures, to (1) avoid the surgical morbidity of 2 operations with 2 fairly intensive rehabilitation periods and (2) immediately offload the cartilage/meniscus grafts in cases of significant malalignment.

[§]References 8, 11, 25, 27, 28, 33, 37, 40, 43.

*Address correspondence to Rachel M. Frank, MD, CU Sports Medicine, Department of Orthopaedic Surgery, University of Colorado School of Medicine, 2150 Stadium Drive, Boulder, CO 80309, USA (email: rmfank3@gmail.com).

[†]CU Sports Medicine, Department of Orthopedics, University of Colorado School of Medicine, Boulder, Colorado, USA.

[‡]Department of Orthopaedic Surgery, Rush University Medical Center, Chicago, Illinois, USA.

Presented at the 43rd annual meeting of the AOSSM, Toronto, Ontario, Canada, July 2017.

The authors declared that they have no conflicts of interest in the authorship and publication of this contribution.

One or more of the authors has declared the following potential conflict of interest or source of funding: B.J.C. holds stock options in Aqua Boom, Biomerix, Giteliscop, Ossio, and Regentis; is a paid consultant for Arthrex, Flexion, Regentis, Smith & Nephew, and Zimmer; receives research support from Aesculap/B.Braun, Arthrex, Geistlich, Medipost, the National Institutes of Health (NIAMS & NICHD), Novartis, Sanofi-Aventis, and Zimmer; IP royalties from Arthrex, DJ Orthopaedics, and Elsevier; and other financial or material support from Athletico, JRF Ortho, Smith & Nephew, and Tornier.

TABLE 2
Data Collected for All Patients Undergoing OCA ± MAT^a

Demographic	Age, sex, BMI, and insurance status (including workers' compensation status)
Preoperative	Mechanism of original injury, type/level of athlete, and number and type of prior ipsilateral knee operations
Intraoperative	Laterality, compartment involved, size of defect relative to size of involved condyle (for femoral condyle procedures), depth of defect, concomitant procedures (including ACL reconstruction and/or osteotomy)
Postoperative	Complications, reoperations, and validated patient-reported outcome scores at a minimum of 2 y after surgery

^aACL, anterior cruciate ligament; BMI, body mass index; MAT, meniscus allograft transplantation; OCA, osteochondral allograft transplantation.

Patients undergoing revision OCA for a failed prior OCA, patients undergoing OCA to the patella or trochlea, as well as patients <15 years old at the time of surgery were excluded. Patients were not excluded for having undergone prior ipsilateral knee surgery (other than prior OCA) or for undergoing concomitant high tibial osteotomy or distal femoral osteotomy procedures at the time of OCA. Data collected for all patients included demographic information, mechanism of injury, medical/surgical history, and intraoperative findings, as described in Table 2. For all patients, pre- and postoperative (minimum 2 years after surgery) validated clinical patient-reported outcome assessments were collected through a combination of electronic and paper surveys, including the Lysholm, International Knee Documentation Committee, Knee injury and Osteoarthritis Outcome Score (KOOS), Western Ontario and McMaster Universities Osteoarthritis Index (WOMAC), and Short Form-12 mental and physical subscales.

The reoperation rate, failure rate, timing of reoperation, procedures performed, findings at surgery, and patient-reported outcome scores were analyzed and compared between the groups. Reoperation was defined as undergoing any subsequent ipsilateral knee procedure after the index OCA. Failure was defined by revision OCA, conversion to knee arthroplasty, or gross appearance of graft failure at second-look arthroscopy. A second-look arthroscopy was performed for any patient with pain and/or swelling after the index OCA after failure of nonoperative management, including physical therapy, oral anti-inflammatories, and corticosteroid injections.

Surgical Technique

The surgical techniques used by the senior author (B.J.C.) in this study for OCA and MAT have been described in detail.^{29,31} In brief, all patients underwent an examination under anesthesia, followed by a diagnostic arthroscopy to assess the status of the chondral defect and meniscus. For patients undergoing OCA with concomitant MAT, the meniscus transplant portion of the procedure was completed first, followed by the OCA portion of the procedure through a miniarthrotomy. Notably, for patients undergoing concomitant MAT, the meniscus repair sutures were not tied until after the osteochondral allograft had been impacted into place; these sutures were tied with the knee in full extension. If concomitant high tibial osteotomy or distal femoral osteotomy was performed, the osteotomy

portion was performed last, after the OCA (and after the MAT among those undergoing it).

Rehabilitation Protocol

The senior author's (B.J.C.) preferred postoperative rehabilitation protocols have also been described.^{29,31} In brief, protected weightbearing was recommended for both patient groups for the first 6 to 8 weeks. Patients undergoing isolated OCA were not braced postoperatively, while patients undergoing MAT combined with OCA were placed in a hinged knee brace for the first 6 to 8 weeks largely to protect the MAT from twisting moments. Early weight-bearing range of motion (0°-90°) was restricted until 4 to 6 weeks after surgery for those undergoing a concomitant MAT. Patients were permitted to progress to sport-specific activities by 6 to 8 months after surgery, provided that proper counseling was delivered to and understanding conveyed by the patient pertaining to the possibility of reinjury with certain high-risk "meniscus-dependent" sports. For those patients undergoing isolated OCA, the senior author's (B.J.C.) position is that unrestricted return to sports poses minimal risk to the allograft if the patient's pain relief and function are acceptable for his or her specific sport.

Statistical Analysis

Statistical analysis was performed through descriptive statistics, chi-square or Fisher exact testing, and Mann-Whitney *U* testing. All reported *P* values are 2-tailed, with an α level of 0.05 detecting significant differences (SPSS Statistics, v 23.0; IBM). According to published data¹⁸ and the KOOS ADL subscale as the primary outcome of interest, an a priori power analysis demonstrated that with an effect size of 0.62 and a power of 0.8, 43 patients were required in each group for this study to be adequately powered.

RESULTS

One hundred patients with a mean ± SD age of 31.7 ± 9.8 years (52 males, 48 females) who underwent OCA (50 without MAT, 50 with MAT) with a follow-up of 4.9 ± 2.7 years (range, 2.0-15.1 years) were included from a total cohort of 180 patients with 2-year clinical follow-up data (Table 3). All 100 patients (100%) underwent at least 1 surgical

TABLE 3
Demographics and Surgical History^a

	OCA Without MAT	OCA With MAT	P Value
Patients	50	50	>.999
Males	27 (54)	25 (50)	.689
Age, y	32.29 ± 10.34	31.19 ± 9.39	.579
BMI, kg/m ²	26.08 ± 4.37	24.98 ± 4.81	.245
Left knee	27 (54)	21 (42)	.230
Workers' compensation cases	11	7	.298
No. of previous operations	2.3 ± 1.30	3.1 ± 1.95	.024
Follow-up duration, y	5.07 ± 2.49	4.77 ± 2.86	.574
Patients with failed prior articular cartilage surgery	29 (58)	16 (32)	.009
Failed OCD ORIF	9	1	.009
Failed MFX	17	14	.517
Failed DeNovo (Zimmer)	0	1	.315
Failed ACI	3	2	.646
Failed OATS	4	1	.169

^aValues are presented as No. (%) or mean ± SD. Bold indicates $P < .05$. ACI, autologous chondrocyte implantation; BMI, body mass index; MAT, meniscus allograft transplantation; MFX, microfracture; OATS, osteochondral autograft transplantation; OCA, osteochondral allograft transplantation; OCD, osteochondritis dissecans; ORIF, open reduction internal fixation.

procedure on the ipsilateral knee before OCA, with the cohort as a whole undergoing 2.7 ± 1.7 ipsilateral knee operations before OCA. Patients undergoing OCA without MAT were significantly more likely to have had a failed prior articular cartilage procedure (osteochondritis dissecans fixation, microfracture, autologous chondrocyte implantation, DeNovo [Zimmer], or osteochondral autograft transplantation) when compared with patients undergoing OCA with MAT ($P = .009$). Ten patients (20%) undergoing OCA without MAT had a previous partial meniscectomy in the compartment where the OCA was performed.

None of the patients in either group underwent concomitant ligament repair or reconstruction surgery. Four patients (8%) undergoing OCA without MAT had concomitant realignment osteotomies, while 5 patients (10%) undergoing OCA with MAT had concomitant realignment osteotomies ($P > .999$) (Table 4). One patient (2%) who had OCA without MAT underwent a concomitant ipsilateral partial meniscectomy.

Among the 50 patients undergoing OCA without MAT, 30 had MFC OCAs, and 20 had LFC OCAs. For the 50 patients undergoing OCA with MAT, 29 had MFC OCAs (including 29 medial MATs), and 21 had LFC OCAs (including 21 lateral MATs). Significantly more patients underwent OCA to the MFC ($n = 59$) than the LFC ($n = 41$, $P < .0001$) (Table 4). There were no significant differences in defect size (OCA without MAT: 435.95 ± 181.52 mm² vs OCA with MAT: 449.40 ± 174.24 mm², $P > .05$) or defect:condyle size ratio (OCA without MAT: 0.20 vs OCA with MAT: 0.19, $P > .05$).

Clinical Outcomes

There were no statistically significant differences in any of the baseline patient-reported outcome scores between those undergoing OCA without MAT and those undergoing OCA with MAT ($P > .05$ for all) (Table 5).

TABLE 4
Concomitant Procedures for Compartment Receiving OCA^a

	OCA Without MAT	OCA With MAT	P Value
Medial OCA	30	29	
Any major concomitant surgery	2	29	.219
Lateral MAT	0	0	>.999
Medial MAT	0	29	<.0001
HTO	2	2	>.999
DFO	0	0	>.999
Lateral OCA	20	21	
Any major concomitant surgery	2	21	<.0001
Lateral MAT	0	21	<.0001
Medial MAT	0	0	>.999
HTO	0	0	>.999
DFO	2	3	.646

^aBold indicates $P < .05$. DFO, distal femoral osteotomy; HTO, high tibial osteotomy; MAT, meniscus allograft transplantation; OCA, osteochondral allograft transplantation.

At final follow-up, patients in both groups experienced statistically significant improvements in Lysholm, IKCD, KOOS, WOMAC, and SF-12 physical subscale outcomes scores as compared with preoperative values ($P < .05$ for all outcome scores for both groups) (Table 5). There were no statistical improvements in SF-12 mental subscale outcome scores in either group ($P > .05$ for both groups). No significant differences in patient-reported outcomes were demonstrated between the groups at final follow-up ($P > .05$ for all).

Complications

There were 3 (6%) complications for patients undergoing OCA without MAT, as opposed to 2 (4%) for patients undergoing OCA with MAT ($P = .646$). The 3 complications in the

TABLE 5
Patient-Reported Outcome Measures Between Patients Undergoing OCA
With and Without MAT Preoperatively and at Final Follow-up^a

	Preoperative			Final Follow-up		
	OCA Without MAT (n = 50)	OCA + MAT (n = 50)	P Value	OCA Without MAT (n = 50)	OCA + MAT (n = 50)	P Value
Lysholm	41.83 ± 20.44	49.48 ± 16.06	.136	69.56 ± 21.39	70.77 ± 17.94	.777
IKDC	35.48 ± 15.43	39.80 ± 15.78	.317	63.19 ± 21.17	66.35 ± 17.61	.455
KOOS						
Pain	55.56 ± 15.69	59.85 ± 15.82	.298	77.45 ± 18.26	80.69 ± 15.00	.376
Symptom	60.14 ± 16.39	57.75 ± 15.65	.570	78.57 ± 17.65	75.91 ± 18.36	.495
ADL	66.12 ± 21.17	69.03 ± 23.31	.619	86.53 ± 17.07	91.92 ± 9.57	.074
Sport	27.40 ± 22.37	30.86 ± 22.48	.574	55.12 ± 27.22	56.90 ± 26.55	.760
QOL	22.12 ± 18.56	29.22 ± 17.59	.135	58.28 ± 25.93	56.10 ± 23.04	.681
WOMAC						
Pain	7.04 ± 3.67	6.41 ± 3.52	.502	3.44 ± 3.18	2.61 ± 2.95	.218
Stiffness	3.20 ± 2.00	3.26 ± 1.72	.906	1.91 ± 1.96	1.86 ± 1.84	.898
Function	23.04 ± 14.39	21.06 ± 15.85	.619	9.16 ± 11.61	5.43 ± 6.57	.073
Overall	2.96 ± 1.99	3.17 ± 1.89	.678	6.56 ± 2.78	6.91 ± 2.14	.516
Symptom rate	4.42 ± 1.76	4.31 ± 2.22	.872	7.24 ± 2.18	7.09 ± 2.20	.772
SF-12						
Physical	34.31 ± 6.83	33.94 ± 5.72	.826	43.47 ± 7.64	46.20 ± 7.40	.099
Mental	51.17 ± 12.96	52.84 ± 11.45	.606	51.42 ± 14.15	54.64 ± 9.34	.217

^aValues are presented as mean ± SD. ADL, activities of daily living; IKDC, International Knee Documentation Committee; KOOS, Knee injury and Osteoarthritis Outcome Score; MAT, meniscus allograft transplantation; OCA, osteochondral allograft transplantation; QOL, quality of life; SF12, Short Form–12; WOMAC, Western Ontario and McMaster Universities Osteoarthritis Index.

non-MAT group were a transient peroneal nerve palsy that fully resolved, local cellulitis requiring oral antibiotics, and a pulmonary embolism from a deep venous thrombosis requiring systemic anticoagulation. The 2 complications in the MAT group were local cellulitis requiring oral antibiotics and postoperative arthrofibrosis requiring arthroscopic lysis of adhesions.

Reoperations

Of the 100 patients, 35 underwent reoperation at 2.8 ± 2.6 years after index OCA. There were no significant differences in the number of patients in either group undergoing reoperation (OCA without MAT: 36% vs OCA with MAT: 34%, *P* = .834) or in the mean time to reoperation (OCA without MAT: 3.43 ± 2.68 years vs OCA with MAT: 2.16 ± 2.41 years, *P* = .149). Of the 35 patients undergoing reoperation, 9 underwent multiple reoperations (range, 1-3 additional reoperations) without any significant differences between the groups (OCA without MAT: 22.2% vs OCA with MAT: 29.4% years, *P* = .711). Of the 35 initial reoperations, 18 (51.43%) were performed within 2 years of the index OCA, with patients undergoing OCA with MAT demonstrating a significantly higher rate of reoperation within this time frame (OCA without MAT: 33.3% vs OCA with MAT: 70.6% years, *P* = .044). Arthroscopic debridement was performed in 32 of these 35 initial reoperations (91.43%), with 26 knees (81.25%) showing arthroscopic evidence of an intact graft. Arthroscopic debridements were performed to smooth any incongruent but not degenerative chondral surfaces in and around the graft. Of the 32 patients receiving debridements, 1 also received a small

posterior medial meniscectomy (initial operative medial OCA without MAT), and 2 underwent loose body excision in the unilateral compartment. Of these 26 knees, 6 knees ultimately progressed to failure at 4.1 ± 2.6 years after OCA.

Failures

Among the 100 cases, 14 (14%) were considered failures at 3.24 ± 1.93 years after index OCA. Of these 14 patients, 6 (42.86%) underwent revision OCA; 5 received subsequent knee arthroplasty (35.71%); and 3 had the appearance of poorly incorporated osteochondral allograft at second-look arthroscopy (21.43%). There were no significant differences between the groups with respect to failure rates (OCA without MAT: n = 7 [14%] vs OCA with MAT: n = 7 [14%], *P* > .999) or time to failure (OCA without MAT: 3.14 ± 0.86 years vs OCA with MAT: 3.34 ± 2.72 years, *P* = .149) (Figure 1). None of the failures in the MAT group were thought to be related to failure of the meniscus allograft.

Medial Versus Lateral OCA

Overall, patients undergoing LFC OCA had superior International Knee Documentation Committee, KOOS sport subscale, and overall WOMAC outcomes scores when compared with patients undergoing MFC OCA (Table 6); no differences were noted between patients undergoing MFC OCA with and without MAT. A significantly greater SF-12 physical subscale score (*P* = .020) was found for lateral OCA without MAT than with MAT at final follow-up (Appendix Table A1, available in the online version of this article).

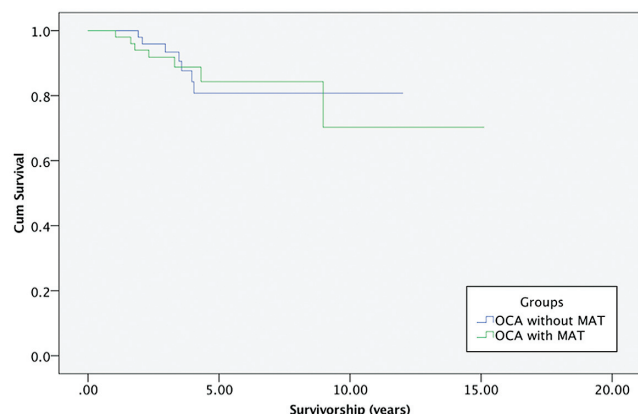


Figure 1. Kaplan-Meier curves comparing survival of OCA grafts for patients who underwent OCA without MAT and patients who underwent OCA with MAT. At a mean \pm SD follow-up of 4.92 ± 2.7 years, patients undergoing OCA without MAT had an overall failure rate of 14% at 3.14 years after OCA, while patients undergoing OCA with MAT had an overall failure rate of 14% at 3.34 years after OCA ($P = .149$). MAT, meniscus allograft transplantation; OCA, osteochondral allograft transplantation.

There were 5 failures after LFC OCA (12.2%): 2 for OCA without MAT and 3 for concomitant MAT ($P = .633$). There were 9 failures of MFC OCA (15.3%): 5 for OCA without MAT and 4 for OCA with MAT ($P = .759$). There was no significant difference in failure rates between OCA procedures based on femoral condyle location ($P = .665$).

DISCUSSION

The principal findings of this study suggest the following: (1) patients undergoing OCA with and without concomitant MAT have favorable clinical outcomes at nearly 5 years after surgery; (2) among patients matched by age, sex, body mass index, and number of prior knee operations, no significant differences in patient-reported outcomes measures were seen between patients undergoing OCA with versus without MAT; and (3) there are no significant differences in reoperation rates, time-to-reoperation failure rates, or time to failure between these groups. These results imply that despite the added surgical time and complexity of concomitant MAT, with appropriate surgical indications, outcomes are favorable, with an 86% OCA graft survival rate at 5 years. This information can be used to counsel patients undergoing OCA with concomitant MAT as part of a knee joint preservation strategy.

MAT for isolated, symptomatic meniscus deficiency and OCA for isolated chondral lesions generally result in good to excellent outcomes when performed in isolation for appropriately indicated patients. Combined meniscus and cartilage lesions are not uncommon, and based on the experience of the senior author (B.J.C.), treatment of both injuries is often necessary to ensure success of any individual procedure.

TABLE 6
Patient-Reported Outcome Measures
Between Involved Compartments at Final Follow-up^a

	Medial OCA	Lateral OCA	<i>P</i> Value
No. of patients	59	41	<.0001
Lysholm	66.8 \pm 21.95	74.81 \pm 14.94	.160
IKDC	60.85 \pm 21.03	70.21 \pm 15.63	.037
KOOS			
Pain	76.02 \pm 17.89	83.18 \pm 14.16	.085
Symptom	75.93 \pm 19.29	79.07 \pm 16.00	.562
ADL	87.29 \pm 15.60	91.91 \pm 11.14	.156
Sport	51.12 \pm 28.01	62.64 \pm 23.71	.047
QOL	53.13 \pm 25.92	62.85 \pm 21.23	.076
WOMAC			
Pain	3.53 \pm 3.21	2.34 \pm 2.78	.076
Stiffness	2.16 \pm 1.96	1.49 \pm 1.37	.196
Function	8.64 \pm 10.60	5.43 \pm 7.67	.131
Overall	6.22 \pm 2.47	7.44 \pm 2.32	.011
Symptom rate	6.90 \pm 2.14	7.56 \pm 2.21	.122
SF-12			
Physical	43.75 \pm 7.53	46.34 \pm 7.54	.220
Mental	52.08 \pm 13.06	54.35 \pm 10.47	.379

^aValues are presented as mean \pm SD. Bold indicates $P < .05$. ADL, activities of daily living; IKDC, International Knee Documentation Committee; KOOS, Knee injury and Osteoarthritis Outcome Score; OCA, osteochondral allograft transplantation; QOL, quality of life; SF-12, Short Form-12; WOMAC, Western Ontario and McMaster Universities Osteoarthritis Index.

Previous biomechanical, animal model, and clinical studies demonstrated the protective role of the meniscus in preventing chondral damage and degeneration.¹¹

While literature on outcomes of MAT with concomitant cartilage procedures is fairly limited, data from the available studies are encouraging. In a systematic review, Harris et al²¹ analyzed 6 studies with 110 patients who underwent articular cartilage repair or restoration (microfracture, osteochondral autograft transplantation, OCA, or autologous chondrocyte implantation) with combined MAT. The authors reported an overall reoperation rate of 49%, higher than that in the present study (38%), and an overall failure rate of 12%, slightly lower than that in the present study (14%). Notably, the authors found that 85% of those failures occurred in relation to the meniscus allograft and not as a result of the articular cartilage procedure. In the present study, none of the failures in the MAT group were thought to be related to failure of the meniscus allograft. Harris et al reported that across all studies, patients experienced improvement in clinical outcomes after surgery, with 2 of the 6 studies demonstrating that articular cartilage surgery with concomitant MAT results in similar outcomes when compared with either technique performed in isolation, consistent with the results in our study.

To our knowledge, only 1 other study in the literature analyzed the outcomes of OCA with concomitant MAT. In 2015, Getgood and colleagues¹⁵ reported on 48 patients undergoing concomitant OCA with MAT at a mean clinical follow-up of 6.8 years. Similar to the present study, the

majority of patients (90%) in their cohort had undergone at least 1 ipsilateral knee surgery before OCA. Despite similarities in several demographic variables between their study and the present study, including patient age and sex, differences in underlying diagnoses and surgical technique make it difficult to compare their outcomes and ours. For example, osteoarthritis or tibial plateau fracture was the underlying diagnosis for 30 of their 48 patients, while no patients in the present study had either of these underlying conditions. Furthermore, 36 of the 48 patients in their study underwent MAT via a compound tibial plateau OCA with the native meniscus attached, while no patients in the present study underwent OCA to the tibia (no compound grafts were utilized). In their series, there was a 54% reoperation rate and a 23% failure rate (11 of 48 patients), with 10 of 11 failures thought to be attributable to a failed meniscus and osteochondral graft. They reported a survivorship of 78% (MAT) and 73% (OCA) at 5 years, lower than the survivorship of 86% found in the present study. This may be attributable to the different patient populations in their study versus ours, as their cohort included patients with more advanced arthritis before allograft transplantation.

The present study is unique in that the matching methodology allowed for the assessment of concomitant MAT as an independent variable affecting outcomes after OCA. With nearly all other critical factors being equal in the 2 groups, including age, sex, body mass index, and number of previous ipsilateral knee operations, we were able to truly isolate the impact of concomitant MAT on clinical outcomes scores, complications, reoperations, and failures. Notably, patients in both groups experienced significantly improved outcomes based on their preoperative scores. Patients with isolated chondral defects without meniscus deficiency often have similar symptoms and physical examination findings when compared with patients with isolated chondral defects with meniscus deficiency. Determining if one or both these injuries are responsible for a given patient's symptoms is exceedingly difficult. As such, determining if MAT should be performed concomitantly with OCA is also extremely challenging, particularly for patients with a history of prior surgery, as even a thorough diagnostic workup with advanced imaging (ie, magnetic resonance imaging) can be difficult to interpret. Certainly, patients who are deemed to be candidates for combined OCA with MAT are different from patients who are candidates for OCA but do not require concomitant MAT. This study did not aim to determine indications for MAT to be performed concomitantly with OCA but rather sought to determine if performing concomitant MAT has any effect on outcomes, reoperation rates, or failure rates after OCA. As many chondral or osteochondral lesions develop following meniscectomy, it is the senior author's (B.J.C.) opinion that ignoring meniscal deficiency at the time of OCA places the osteochondral allograft at risk for failure in addition to increasing the risk that postoperative pain relief will remain unacceptable to the patient being treated. Importantly, despite the added complexity of performing concomitant MAT with OCA, no differences in

complications, reoperation rates, or failure rates were found between otherwise similar groups of patients undergoing OCA with and without MAT.

Limitations

Limitations of this study include its relatively small sample size and inclusion of patients in a nonconsecutive fashion. To specifically analyze the presence or absence of concomitant MAT as an independent variable, patients undergoing OCA with MAT were matched on the basis of age ± 3 years, sex, body mass index ± 5 kg/m² and the number of previous ipsilateral knee operations ± 1 in a 1-to-1 format to patients undergoing OCA without MAT. While this matching technique is effective at isolating the variable of interest and was successfully utilized in prior studies,¹³ analyzing patients nonconsecutively may introduce selection bias. Fortunately, a previously published study based on a similar patient population with a consecutive series of OCA cases (not selected by the matching criteria used here) demonstrated overall outcomes and reoperation rates consistent with those in the present study; thus, any effect of selection bias is likely clinically less relevant.¹⁴ As in the limitations of other studies analyzing the outcomes of cartilage and meniscus restoration surgery, it is difficult to conclude if the outcomes and reoperation rates described here are influenced by the combined effects of concomitant procedures, as opposed to being a reflection of the OCA procedure itself. Finally, while clinical outcomes were assessed at a mean of 5 years after surgery, this study is limited by a lack of imaging follow-up. In the senior author's (B.J.C.) practice, imaging beyond the initial postoperative radiographs is obtained only if patients are symptomatic, and because of funding constraints and the unclear relevance of radiographic changes in the absence of symptoms, radiographs at final follow-up were not obtained for this study.

CONCLUSION

These results imply that with appropriate surgical indications to address meniscus deficiency for patients otherwise indicated for an osteochondral allograft, despite the added surgical time and complexity of concomitant MAT, the outcomes are favorable, with an 86% OCA graft survivorship at 5 years. This information can be used to counsel patients undergoing concomitant MAT as part of a knee joint preservation strategy.

REFERENCES

1. Aubin PP, Cheah HK, Davis AM, Gross AE. Long-term followup of fresh femoral osteochondral allografts for posttraumatic knee defects. *Clin Orthop Relat Res*. 2001;391:S318-S327.
2. Bhosale AM, Myint P, Roberts S, et al. Combined autologous chondrocyte implantation and allogenic meniscus transplantation: a biological knee replacement. *Knee*. 2007;14(5):361-368.
3. Bonasia DE, Amendola A. Combined medial meniscal transplantation and high tibial osteotomy. *Knee Surg Sports Traumatol Arthrosc*. 2010;18(7):870-873.

^{||}References 8, 11, 25, 27, 28, 33, 37, 40, 43.

4. Briggs DT, Sadr KN, Pulido PA, Bugbee WD. The use of osteochondral allograft transplantation for primary treatment of cartilage lesions in the knee. *Cartilage*. 2015;6(4):203-207.
5. Brittberg M, Lindahl A, Nilsson A, Ohlsson C, Isaksson O, Peterson L. Treatment of deep cartilage defects in the knee with autologous chondrocyte transplantation. *N Engl J Med*. 1994;331(14):889-895.
6. Cameron JL, McCauley JC, Kermanshahi AY, Bugbee WD. Lateral opening-wedge distal femoral osteotomy: pain relief, functional improvement, and survivorship at 5 years. *Clin Orthop Relat Res*. 2015;473(6):2009-2015.
7. Chahal J, Gross AE, Gross C, et al. Outcomes of osteochondral allograft transplantation in the knee. *Arthroscopy*. 2013;29(3):575-588.
8. Choate CJ, Kim SE, Hudson CC, Spreng D, Pozzi A. Effect of lateral meniscectomy and osteochondral grafting of a lateral femoral condylar defect on contact mechanics: a cadaveric study in dogs. *BMC Vet Res*. 2013;9:53.
9. Cole BJ, Pascual-Garrido C, Grumet RC. Surgical management of articular cartilage defects in the knee. *J Bone Joint Surg Am*. 2009;91(7):1778-1790.
10. Cvetanovich GL, Yanke AB, McCormick F, Bach BR Jr, Cole BJ. Trends in meniscal allograft transplantation in the United States, 2007 to 2011. *Arthroscopy*. 2015;31(6):1123-1127.
11. Dempsey AR, Wang Y, Thorlund JB, et al. The relationship between patellofemoral and tibiofemoral morphology and gait biomechanics following arthroscopic partial medial meniscectomy. *Knee Surg Sports Traumatol Arthrosc*. 2013;21(5):1097-1103.
12. Frank RM, Cole BJ. Complex cartilage cases in the athletic patient: advances in the malalignment, articular defects, and meniscal insufficiency. *Phys Sportsmed*. 2013;41(4):41-52.
13. Frank RM, Lee S, Bush-Joseph CA, Salata MJ, Mather RC 3rd, Nho SJ. Outcomes for hip arthroscopy according to sex and age: a comparative matched-group analysis. *J Bone Joint Surg Am*. 2016;98(10):797-804.
14. Frank RM, Lee S, Levy D, et al. Osteochondral allograft transplantation of the knee. *Am J Sports Med*. 2017;45(4):864-874.
15. Getgood A, Gelber J, Gortz S, De Young A, Bugbee W. Combined osteochondral allograft and meniscal allograft transplantation: a survivorship analysis. *Knee Surg Sports Traumatol Arthrosc*. 2015;23(4):946-953.
16. Gomoll AH, Farr J, Gillogly SD, Kercher J, Minas T. Surgical management of articular cartilage defects of the knee. *J Bone Joint Surg Am*. 2010;92(14):2470-2490.
17. Gomoll AH, Kang RW, Chen AL, Cole BJ. Triad of cartilage restoration for unicompartmental arthritis treatment in young patients: meniscus allograft transplantation, cartilage repair and osteotomy. *J Knee Surg*. 2009;22(2):137-141.
18. Gracitelli GC, Meric G, Briggs DT, et al. Fresh osteochondral allografts in the knee: comparison of primary transplantation versus transplantation after failure of previous subchondral marrow stimulation. *Am J Sports Med*. 2015;43(4):885-891.
19. Gracitelli GC, Meric G, Pulido PA, McCauley JC, Bugbee WD. Osteochondral allograft transplantation for knee lesions after failure of cartilage repair surgery. *Cartilage*. 2015;6(2):98-105.
20. Gross AE, Shasha N, Aubin P. Long-term followup of the use of fresh osteochondral allografts for posttraumatic knee defects. *Clin Orthop Relat Res*. 2005;435:79-87.
21. Harris JD, Cavo M, Brophy R, Siston R, Flanigan D. Biological knee reconstruction: a systematic review of combined meniscal allograft transplantation and cartilage repair or restoration. *Arthroscopy*. 2011;27(3):409-418.
22. Harris JD, Hussey K, Saltzman BM, et al. Cartilage repair with or without meniscal transplantation and osteotomy for lateral compartment chondral defects of the knee: case series with minimum 2-year follow-up. *Orthop J Sports Med*. 2014;2(10):2325967114551528.
23. Harris JD, Hussey K, Wilson H, et al. Biological knee reconstruction for combined malalignment, meniscal deficiency, and articular cartilage disease. *Arthroscopy*. 2015;31(2):275-282.
24. Harris JD, McNeilan R, Siston RA, Flanigan DC. Survival and clinical outcome of isolated high tibial osteotomy and combined biological knee reconstruction. *Knee*. 2013;20(3):154-161.
25. Jiang D, Ao YF, Gong X, Wang YJ, Zheng ZZ, Yu JK. Comparative study on immediate versus delayed meniscus allograft transplantation: 4- to 6-year follow-up. *Am J Sports Med*. 2014;42(10):2329-2337.
26. Knutsen G, Engebretsen L, Ludvigsen TC, et al. Autologous chondrocyte implantation compared with microfracture in the knee: a randomized trial. *J Bone Joint Surg Am*. 2004;86(3):455-464.
27. Lee BS, Bin SI, Kim JM. Articular cartilage degenerates after subtotal/total lateral meniscectomy but radiographic arthrosis progression is reduced after meniscal transplantation. *Am J Sports Med*. 2016;44(1):159-165.
28. Lee BS, Bin SI, Kim JM, Kim JH, Han GW. Proper cartilage status for meniscal allograft transplantation cannot be accurately determined by patient symptoms. *Am J Sports Med*. 2016;44(3):646-651.
29. McCormick F, Harris JD, Abrams GD, et al. Survival and reoperation rates after meniscal allograft transplantation: analysis of failures for 172 consecutive transplants at a minimum 2-year follow-up. *Am J Sports Med*. 2014;42(4):892-897.
30. McCormick F, Harris JD, Abrams GD, et al. Trends in the surgical treatment of articular cartilage lesions in the United States: an analysis of a large private-payer database over a period of 8 years. *Arthroscopy*. 2014;30(2):222-226.
31. McCulloch PC, Kang R, Cole BJ. Osteochondral allografts for large defects in the knee. *Tech Knee Surg*. 2006;5(3):165-173.
32. Meric G, Gracitelli GC, Gortz S, De Young AJ, Bugbee WD. Fresh osteochondral allograft transplantation for bipolar reciprocal osteochondral lesions of the knee. *Am J Sports Med*. 2015;43(3):709-714.
33. Mills PM, Wang Y, Cicuttini FM, et al. Tibio-femoral cartilage defects 3-5 years following arthroscopic partial medial meniscectomy. *Osteoarthritis Cartilage*. 2008;16(12):1526-1531.
34. Moran CJ, Pascual-Garrido C, Chubinskaya S, et al. Restoration of articular cartilage. *J Bone Joint Surg Am*. 2014;96(4):336-344.
35. Noyes FR, Barber-Westin SD. Meniscus transplantation: indications, techniques, clinical outcomes. *Instr Course Lect*. 2005;54:341-353.
36. Oliver-Welsh L, Griffin JW, Meyer MA, Gitelis ME, Cole BJ. Deciding how best to treat cartilage defects. *Orthopedics*. 2016;39(6):343-350.
37. Rongen JJ, Hannink G, van Tienen TG, van Luijk J, Hooijmans CR. The protective effect of meniscus allograft transplantation on articular cartilage: a systematic review of animal studies. *Osteoarthritis Cartilage*. 2015;23(8):1242-1253.
38. Rue JP, Yanke AB, Busam ML, McNickle AG, Cole BJ. Prospective evaluation of concurrent meniscus transplantation and articular cartilage repair: minimum 2-year follow-up. *Am J Sports Med*. 2008;36(9):1770-1778.
39. Saris DBF, Vanlauwe J, Victor J, et al. Treatment of symptomatic cartilage defects of the knee: characterized chondrocyte implantation results in better clinical outcome at 36 months in a randomized trial compared to microfracture. *Am J Sports Med*. 2009;37(1):10S-19S.
40. Sturmeiks DL, Besier TF, Mills PM, et al. Knee joint biomechanics following arthroscopic partial meniscectomy. *J Orthop Res*. 2008;26(8):1075-1080.
41. Verdonk PC, Demurie A, Almqvist KF, Veys EM, Verbruggen G, Verdonk R. Transplantation of viable meniscal allograft: survivorship analysis and clinical outcome of one hundred cases. *J Bone Joint Surg Am*. 2005;87(4):715-724.
42. Verdonk PC, Verstraete KL, Almqvist KF, et al. Meniscal allograft transplantation: long-term clinical results with radiological and magnetic resonance imaging correlations. *Knee Surg Sports Traumatol Arthrosc*. 2006;14(8):694-706.
43. Wang Y, Dempsey AR, Lloyd DG, et al. Patellofemoral and tibiofemoral articular cartilage and subchondral bone health following arthroscopic partial medial meniscectomy. *Knee Surg Sports Traumatol Arthrosc*. 2012;20(5):970-978.